



PATIENT

Biscuit Rinehart

SPECIES

Feline

BREED

DSH

SEX

Male Neutered

AGE

2 years

WEIGHT

12.40lbs

INTERPRETED BY

Maggie Machen Lamy,
DVM, DACVIM
(Cardiology)

IMAGING PERFORMED BY

Amanda Crook, SDEP

HOSPITAL NAME

River Edge Pet Medical
Center

REFERRING VET

Dr. Gray

INVOICE

46956

DATE

2/24/26

PRESENTING CLINICAL SIGNS

History: Acute onset increased respiratory rate. On injectable Lasix overnight. Labs: WNL. CXR showed cardiomegaly, elevated trachea and CHF.

RADIOGRAPHIC FINDINGS *NOTE: Images submitted for supplemental cardiac information only. Cardiomegaly with evidence of CHF.

ECHOCARDIOGRAM FINDINGS

2D, m-mode, color flow and doppler imaging is available. The left ventricular wall is moderately increased in dimension with a normal chamber size. There is a mildly hyperechoic endocardium consistent with fibrosis. The papillary muscles are mildly remodeled and hypertrophied. The endocardium also appears remodeled. Adequate myocardial function. The left atrium is moderately dilated in size. No obvious spontaneous contrast seen. The right atrium is normal in size. The right ventricle appears normal. The mitral valve is normal in structure and mobility. Blood flow through both the LVOT and RVOT is normal in velocity. Trace MR. No TR. Scant pericardial effusion seen. No pleural effusion. No obvious cardiac tumors.

CARDIAC CHART

FELINE CARDIAC PARAMETERS	BODY WEIGHT (kg)	HR (BPM)	IVSd (cm) (Moise, Pipers)	LVIDd (cm) (Moise, Pipers)	LVWd (cm) (Moise, Pipers)	FS (%)	EF (%)
NORMAL PARAMETER	-----	150-240	0.35-0.55	<2 (mean 1.5)	3.5-0.55	35-67	80-100
PATIENT	5.6	NM	0.83	1.06	0.70	54	88
FELINE CARDIAC PARAMETERS	LA/AO (Boon)	LA/AO HEART BASE (Swe) (Abbott)	LA 2D short axis Base view (cm) (Abbott)		LVOT VEL (m/s)	RVOT VEL (m/s)	E max (m/s)
NORMAL	<1.5	<1.3	<1.2		<1.6	<1.3	<0.9
PATIENT	1.7	1.7	1.6		0.9	0.7	NM
<p><i>*Note: All measurements based upon multi-modal images and methods. An average value is reported.</i></p> <p>Adapted from June Boon, Veterinary Echocardiography, 1998 Abbott J & MacLean H JVIM 2006;20: 111-119, Moise et al. Am J Vet Res 47:1476, 1986. Pipers et al. Am J Vet Res 40:882, 1979.</p>							

INTERPRETATION OF THE FINDINGS & FURTHER RECOMMENDATIONS

Hypertrophic cardiomyopathy (HCM) is a rule out diagnosis for LV hypertrophy once a patient is confirmed euthyroid and normotensive. Both should be considered in this case, although given the age of the patient, primary disease is suspected. The left atrium is moderately enlarged, indicating risk for spontaneous CHF and/or blood clot events going forward. No additional structural issues are identified.

Given these findings and scant pericardial effusion, the diagnosis of CHF is supported, and full cardiac support should be instituted as below. It is worth mentioning that moderate LA dilation



PATIENT

Biscuit Rinehart

SPECIES

Feline

BREED

DSH

SEX

Male Neutered

AGE

2 years

WEIGHT

12.40lbs

INTERPRETED BY

Maggie Machen Lamy,
DVM, DACVIM
(Cardiology)

IMAGING PERFORMED BY

Amanda Crook, SDEP

HOSPITAL NAME

River Edge Pet Medical
Center

REFERRING VET

Dr. Gray

INVOICE

46956

DATE

2/24/26

is somewhat surprising to develop organic CHF, and contributing factors should be considered (any history of fluid or steroid therapy, etc.). Regardless, continued treatment is recommended as below. Steroid or fluid therapy should certainly be avoided in this case.

Continued hospitalization should be considered depending on patients' stability. The mean survival time for cats with CHF is 8-12 months; however, most cats are able to maintain a good quality of life on medications. Patient will always be at high risk for recurrent episodes of CHF and development of blood clots in the future. Monitoring of sleeping breathing rates at home is recommended as the best way to screen for recurrent CHF at home.

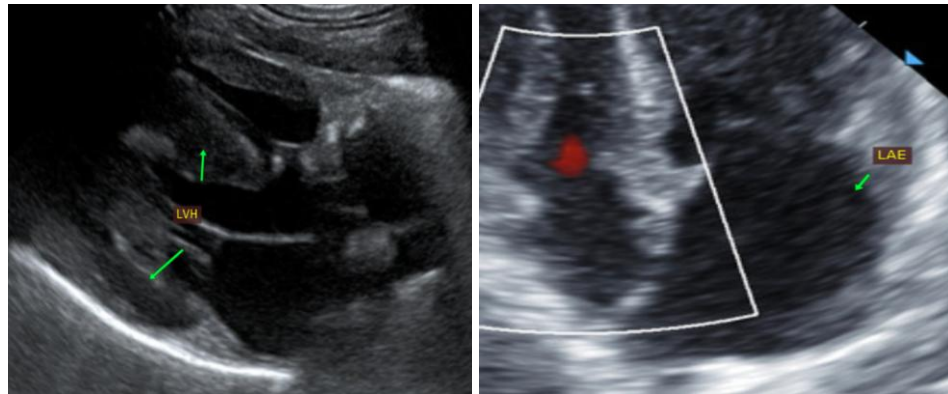
PLAN

Continue injectable Lasix dose/hospitalization until stable. Baseline ECG and BP are strongly recommended. Once stable, discharge on the following: Administer diuretic 1-2mg/kg PO q12h. Administer Pimobendan 1.25mg PO q12h. If able, administer blood thinner Clopidogrel (Plavix) 75mg tablets; give ¼ tab orally once daily (NOTE: this medication is very bitter on the cut edges).

Monitor renal values and BP in 1-2 weeks then every 3-4 months lifelong. If doing well and BP >130mmHg, institute ACEI 0.5mg/kg PO q12h. If difficult to medicate or hypotensive, do not utilize.

A recheck echocardiogram is recommended in 6 months to assess progression.

IMAGES



The information and recommendations provided are based on the images presented by the referring veterinarian. No evaluation can be communicated regarding pathology that was not visible in the image/video clips provided.

Thank you for this referral. This report was generated using transcription software, and minor dictation errors may be present. If the clinical or image interpretation does not parallel your findings or if I can be of any further assistance, please contact me.

Maggie Machen Lamy, DVM

Diplomate of the American College of Veterinary Internal Medicine (Cardiology)

info@sonopath.com